Outcomes of Tissue Expander/Implant Breast Reconstruction in the Setting of Prereconstruction Radiation

Elliot M. Hirsch, M.D.
Akhil K. Seth, M.D.
Gregory A. Dumanian, M.D.
John Y. S. Kim, M.D.
Thomas A. Mustoe, M.D.
Robert D. Galiano, M.D.
Neil A. Fine, M.D.

Chicago, Ill.

Background: Although the effects of postoperative radiation on tissue expander breast reconstruction are well documented, few data exist regarding the effects of prereconstruction radiation. This study evaluates the outcomes of tissue expander breast reconstruction in women with prereconstruction radiation.
Methods: This study retrospectively evaluated two treatments: (1) mastectomy without reconstruction followed by postoperative radiation and delayed reconstruction (10 patients) and (2) failed breast-conserving therapy (lumpectomy plus radiotherapy) necessitating mastectomy and immediate reconstruction (66 patients). Procedures were performed at Northwestern Memorial Hospital between August of 1999 and July of 2008. Average follow-up was 35 months.
Results: In both groups, approximately 60 percent of patients successfully completed two stages of reconstruction. Overall complication rates, including major and minor complications, were 70 percent per reconstruction (37 percent first stage, 45 percent second stage) for immediate reconstruction and 50 percent per reconstruction (20 percent first stage, 38 percent second stage) for delayed reconstruction. No differences in complication rates were observed based on age, smoking status, body mass index, or timing between radiation and surgery ($p > 0.05$).
Conclusions: When discussing expander/implant reconstruction with patients who have a history of prior breast radiotherapy, a frank discussion of the risks, benefits, and alternatives should occur. If a 40 percent total explantation or conversion to flap rate is truly understood by the patient, and if immediate autologous breast reconstruction is to be avoided, then the patient may proceed with tissue expander breast reconstruction. For patients who wish to avoid additional scars or more invasive procedures, however, this study demonstrates that they have a 60 percent chance of success. (*Plast. Reconstr. Surg.* 129: 354, 2012.)
CLINICAL QUESTION/LEVEL OF EVIDENCE: Therapeutic, III.

Although the effects of postmastectomy, postreconstruction radiotherapy on tissue expander/implant breast reconstruction have previously been documented in the literature,[1] there is scant information regarding the complication rates of tissue expander/implant breast reconstruction in patients with prereconstruction radiation. Typically, these patients present in two ways: mastectomy without reconstruction followed by postmastectomy radiation therapy and delayed reconstruction, or failed breast-conserving therapy (lumpectomy plus radiotherapy) necessitating mastectomy and reconstruction. This creates a dilemma for the recon-

From the Division of Plastic and Reconstructive Surgery, Northwestern University Feinberg School of Medicine.
Received for publication April 10, 2011; accepted August 23, 2011.
Presented at the Midwestern Association of Plastic Surgeons 49th Annual Scientific Meeting, in Chicago, Illinois, May of 2010, and at the 56th Annual Meeting of the Plastic Surgery Research Council, in Louisville, Kentucky, May of 2011.
Copyright ©2012 by the American Society of Plastic Surgeons
DOI: 10.1097/PRS.0b013e31823ae8b1

Disclosure: *The authors have no financial interest in any of the products mentioned in this article. They received no funding from the manufacturers of any products mentioned in this article and have no corporate or financial affiliations with the manufacturers.*

Copyright © American Society of Plastic Surgeons. Unauthorized reproduction of this article is prohibited.

structive surgeon, as the deleterious effects of radiation on breast reconstruction are well documented[1] and are unavoidably present in these patient groups.

Currently, the published data regarding the outcomes of these procedures are somewhat contradictory, with some investigators finding that a history of prior radiotherapy is not a significant predictor of postoperative complications in tissue expander/implant reconstruction[2] and others suggesting that "successful two-stage device reconstruction after previous breast irradiation is the exception rather than the rule."[3] Thus, the goal of this study was to evaluate the outcomes of patients who underwent tissue expander/implant breast reconstruction in the setting of prereconstruction radiation.

PATIENTS AND METHODS

The charts of 76 patients who had a history of chest wall and breast radiation and subsequently underwent tissue expander/implant breast reconstruction at Northwestern Memorial Hospital between August of 1999 and July of 2008 were retrospectively reviewed. Mastectomies were performed by seven attending general surgeons, and reconstructive procedures were performed by six attending plastic surgeons. The reconstructive sequences used in this study were described by the authors in a prior publication.[4] In general, the tissue expanders were inserted in either an immediate or delayed fashion. Expansion began approximately 10 to 14 days postoperatively or when deemed appropriate by the attending surgeon

Fig. 1. This patient had a history of breast-conserving therapy on her left breast followed by bilateral mastectomy and immediate tissue expander/implant reconstruction. (*Right*) The patient is shown at 26 months after the initial reconstructive procedure.

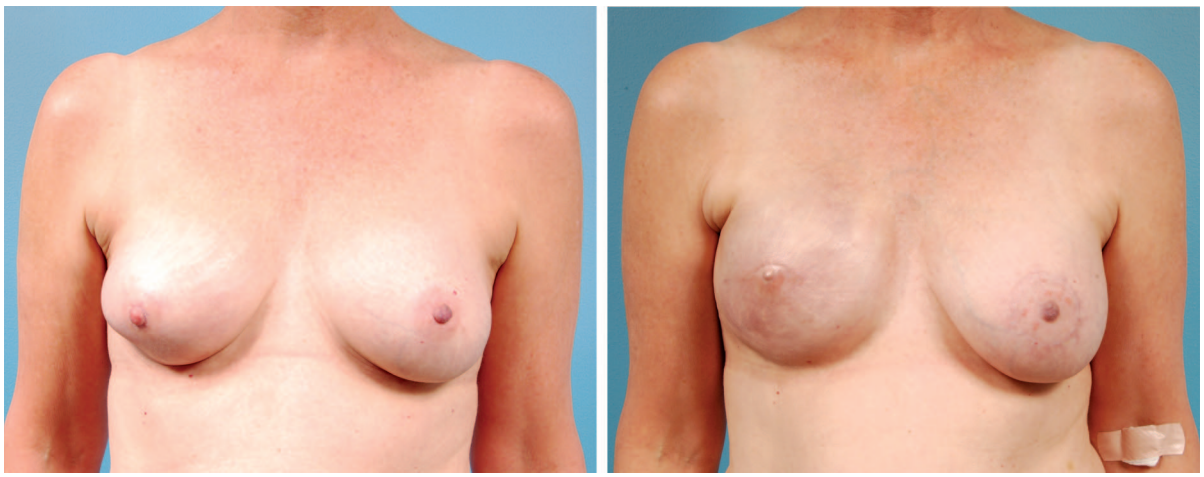

Fig. 2. This patient had a history of breast-conserving therapy on her right breast followed by right mastectomy and immediate tissue expander/implant reconstruction and left-breast, two-stage mastopexy augmentation. (*Right*) The patient is shown at 13 months after the initial reconstructive procedure.

Copyright © American Society of Plastic Surgeons. Unauthorized reproduction of this article is prohibited.

and was carried out until one expansion over the desired volume was achieved. Once this was complete, the tissue expanders were exchanged for permanent implants (Figs. 1 through 4).

For the purpose of analysis, patients were divided into two groups. The first group (n = 10 patients; 10 radiated breasts) underwent mastectomy followed by postoperative radiation with no initial reconstruction. These patients underwent tissue expander/implant reconstruction in a delayed fashion after having completed mastectomy and postoperative radiation. The second group of patients (n = 66 patients; 71 radiated breasts) had previously undergone breast-conserving therapy and experienced a cancer recurrence. They then presented for mastectomy, which was followed by tissue expander/implant reconstruction in immediate fashion. It is important to note that in both groups, only patients with acceptable skin appearance were offered tissue expander/implant reconstruction. Patients with skin appearance demonstrating severe sequelae of radiation therapy (significant erythema or fibrosis) were offered other forms of reconstruction (Figs. 5 and 6).

In this study, only procedures that occurred in radiated breasts were analyzed. For example, if the patient had a bilateral procedure and only one side had been previously radiated, then only the previously radiated side was included in this analysis.

Demographic factors, surgical and oncologic factors, and specific information about complica-

Fig. 3. This patient underwent bilateral mastectomy followed by postmastectomy radiation therapy on her right breast and then delayed bilateral tissue expander/implant reconstruction. (*Right*) The patient is shown at 15 months after the initial reconstructive procedure.

Fig. 4. This patient underwent bilateral mastectomy followed by postmastectomy radiation therapy on her right breast and then delayed bilateral tissue expander/implant reconstruction. (*Right*) The patient is shown at 59 months after the initial reconstructive procedure.

Copyright © American Society of Plastic Surgeons. Unauthorized reproduction of this article is prohibited.

Fig. 5. This patient had a history of breast-conserving therapy on her right breast with acceptable preoperative skin appearance. Her tissue expander extruded on the right breast, however, and ultimately was explanted.

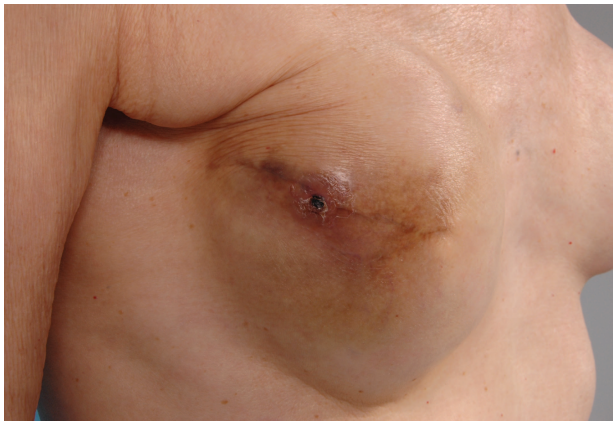

Fig. 6. Close-up of site of eventual extrusion.

tions and revisions were recorded. Complications were divided into minor complications, major complications requiring surgical intervention, and major complications requiring explantation or conversion to flap. The classification of complications is shown in Table 1.

Complaints of pain/tightness and poor cosmesis were only included as complications if they required surgical revision. Erythema or infection treated with oral antibiotics was not included as a complication. Multiple linear regression analysis was used to determine the statistical significance of the results.

RESULTS

In the first group of patients (previous mastectomy followed by postmastectomy radiation therapy with tissue expander/implant reconstruction performed in a delayed fashion), the average age was 48 years (range, 33 to 68 years). The average body mass index was 26.1 kg/m^2 (range, 16.6 to 36.6 kg/m^2). The average tissue expander volume was 370 cc (range, 250 to 600 cc), the average fill volume was 162 cc (range, 30 to 200 cc), and the average permanent implant volume was 396 cc (range, 225 to 800 cc). The average time between the completion of radiation and the first procedure was 48 months (range, 4 to 180 months). Only one patient reported smoking in the past month. There were a total of five complications in the 10 delayed reconstructions, and the distribution of these complications per stage is shown in Table 2.

Among this group, 10 patients (10 breasts) underwent primary tissue expander insertion. Eight patients (eight breasts) went on to tissue

Table 1. Classification of Complications

Minor Complications	Major Complications Requiring Surgical Correction	Major Complications Requiring Explantation or Conversion to Flap
Minor wound healing abnormalities	Major wound healing abnormalities	Implant exposure
Minor mastectomy flap necrosis	Major mastectomy flap necrosis	Pain/tightness
Seroma treated by percutaneous drainage	Threatened exposure	Infection
	Pain/tightness	
	Poor cosmesis	
	Injection port migration	
	Implant deflation	
	Infection requiring drainage	

Copyright © American Society of Plastic Surgeons. Unauthorized reproduction of this article is prohibited.

Table 2. Complication Rates for the Group That Underwent Previous Mastectomy Followed by Postmastectomy Radiation Therapy, with Tissue Expander/Implant Reconstruction Performed in a Delayed Fashion

Delayed	No. of Patients	No. of Breasts	Minor Complication	Major Requiring Surgical Intervention	Major Requiring Explantation or Flap	Total	Overall Complication Rate (% per Patient)	Overall Complication Rate (% per Breast)
Tissue expander insertion	10	10	0	0	2	2 (in 2 patients)	20	20
Tissue expander/implant exchange	8	8	0	1	2	3 (in 2 patients)	37.5	37.5
Total			0	1	4	5		

expander/implant exchange, and six patients (six breasts) successfully completed this stage of reconstruction for a completion rate of 60 percent per patient (60 percent per breast) at an average follow-up time of 38 months. Further analysis of the group that experienced major complications requiring explantation or conversion to flap is shown in Table 3.

Age, body mass index, smoking status, and time between the completion of radiation and the first reconstruction procedure did not have any statistically significant impact on overall complication rates, major complication requiring surgical correction alone, or major complication requiring explantation or flap alone ($p > 0.05$ in all cases). In the second group of patients (previous breast-conserving therapy and later presentation for mastectomy followed by tissue expander/implant reconstruction in immediate fashion), the average age was 53 years (range, 21 to 77 years). The average body mass index was 25.1 kg/m^2 (range, 17.9 to 46.9 kg/m^2). The average tissue expander volume was 366 cc (range, 150 to 850 cc), the average fill volume was 134 cc (range, 0 to 550 cc), and the average permanent implant volume was 418 cc (range, 210 to 800 cc). The average time between the completion of radiation and the first procedure was 81 months (range, 1 to 288 months). Ten patients reported smoking in the past month. There were a total of 49 complications in the 71 immediate reconstructions, and the distribution of these complications per stage is shown in Table 4.

In this group, four patients experienced recurrence of their cancer and either chose to have their implants explanted or did not continue with reconstruction. In addition, one patient chose not to proceed with implant exchange and electively underwent explantation, one patient underwent an adjustable implant insertion rather than a tissue expander insertion and did not require any additional procedures, and one patient chose not to proceed after undergoing tissue expander insertion and did not undergo explantation.

Among this group, 66 patients (71 breasts) underwent immediate primary tissue expander in-

Table 3. Reasons for Explantation or Conversion to Flap in the Delayed Reconstruction Group

Etiology of Major Complication Requiring Explantation or Flap	Pain or Tightness	Infection	Poor Cosmesis
Tissue expander insertion	1	1	0
Tissue expander/implant exchange	0	1	1

Copyright © American Society of Plastic Surgeons. Unauthorized reproduction of this article is prohibited.

Table 4. Complication Rates for the Group That Underwent Previous Breast-Conserving Therapy and Later Presentation for Mastectomy Followed by Tissue Expander/Implant Reconstruction in Immediate Fashion

Immediate	No. of Patients	No. of Breasts	Minor Complication	Major Requiring Surgical Intervention	Major Requiring Explantation or Flap	Total	Overall Complication Rate (% per Patient)	Overall Complication Rate (% per Breast)
Tissue expander insertion	66	71	6	8	12	26 (in 25 patients)	40	37
Tissue expander/implant exchange	49	51	0	14	9	23 (in 19 patients)	47	45
Total			6	22	21			

sertion following mastectomy. A total of 49 patients continued on to tissue expander exchange, and 40 patients (42 breasts) successfully completed this stage of reconstruction for a completion rate of 62 percent per patient (61 percent per breast) at an average follow-up time of 35 months. Further analysis of the group that experienced major complications requiring explantation or conversion to flap is shown in Table 5.

Age, body mass index, smoking status, the use of tumescent solution, and time between the completion of radiation and the first reconstruction procedure did not have any statistically significant impact on overall complication rates, major complication requiring surgical correction alone, or major complication requiring explantation or flap alone ($p > 0.05$ in all cases). Of note, among the patients in the immediate group who reported smoking within the past month ($n = 10$), there was a 100 percent overall complication rate with a 60 percent explantation or conversion to flap rate. There was, however, no statistically significant association between smoking and increased complication rates. The successful completion rate of the overall procedure was 40 percent among smokers.

DISCUSSION

As mentioned previously, the effects of postreconstruction radiation on different techniques of breast reconstruction are well documented.[1,5,6] Multiple studies demonstrate increased complication rates in the setting of postreconstruction radiation (especially after tissue expander/implant reconstruction).[1,3,6–9] Limited data, however, exist regarding the effectiveness of tissue expander/implant breast reconstruction when the patients underwent prereconstruction radiotherapy. Most published studies that attempt to evaluate this cohort are limited by small sample sizes or do not directly address the question of prereconstruction radiation in the setting of tissue expander/implant reconstruction in the previously radiated breast.[5,10–13] Consequently, the complication rates for this patient group appear to have a fairly wide range, from 35 to 75 percent,[1,10–12] and there is no consensus as to what are the success rates of tissue expander/implant breast reconstruction in this patient population.

This is the largest study to date that specifically evaluates the outcomes of tissue expander/implant breast reconstruction in patients who have previously undergone radiation therapy. The observed complication rate was high, with an overall complication rate including both major and minor complications of 70 percent per reconstruc-

Copyright © American Society of Plastic Surgeons. Unauthorized reproduction of this article is prohibited.

Table 5. Reasons for Explantation or Conversion to Flap in the Immediate Reconstruction Group

Etiology of Major Complication Requiring Explantation or Flap	Pain or Tightness	Exposure	Infection	Threatened Exposure
Tissue expander insertion	4	4	4	0
Tissue expander/implant exchange	2	2	4	1

tion (37 percent first stage, 45 percent second stage) in the immediate reconstruction group and 50 percent per reconstruction (20 percent first stage, 38 percent second stage) in the delayed reconstruction group. The higher overall complication rates in the immediate reconstruction group were due to an increased number of minor complications and major complications requiring surgical correction, the vast majority of which were related to difficulties with mastectomy flap healing. This type of problem is comparably much less of an issue in delayed reconstruction, given that at the time of tissue expander insertion, the mastectomy flaps have established their blood supply. Although the difference in complication rates and types of complications between the immediate and delayed groups is notable, the successful completion rate was approximately 60 percent in each group.

It is important to note that in both groups, only patients with acceptable preoperative skin appearance were offered tissue expander/implant reconstruction, which theoretically should have minimized the occurrence of wound-healing problems and other radiation-related complications. The immediate group, however, still experienced a high complication rate, which indicates that an acceptable preoperative skin appearance does not guarantee that the reconstruction will proceed without complication.[3] The unreliability of the skin appearance to predict the outcome of the procedure is likely due to the fact that in the immediate reconstruction group, the combined effects of the radiation and the mastectomy skin flap are not apparent until after the reconstruction has been performed.

Consequently, patients who might not have been eligible for tissue expander/implant reconstruction were able to undergo this treatment but experienced a higher complication rate. In the delayed group, the combined effects of radiation and the mastectomy skin flaps were evident and patients who may have experienced complications were not offered tissue expander/implant reconstruction. The fact that both groups still experienced an approximately 30 to 40 percent explantation or conversion to flap rate further confirms that the postoperative complication rate cannot fully be predicted by an "acceptable" preoperative skin appearance. Moreover, the effects of radiation do not appear to be tempered by time, as no relationship was found between the timing of radiation with respect to the first stage of reconstruction and the development of complications.

CONCLUSIONS

When discussing potential tissue expander/implant reconstruction with patients who have a history of prior breast irradiation, a frank discussion of the risks, benefits, and alternatives should occur. Effective communication between surgeons and patients is critical, and patients should be counseled that not only is there is a high likelihood that they will experience some form of a complication that may require additional procedures, there is reasonable chance that they could lose their implants. Many patients will have difficulty appreciating these difficulties and disappointments. If a 30 to 40 percent total explantation or conversion to flap rate is truly understood by the patient and if for other reasons immediate autologous breast reconstruction is to be avoided, then the patient may proceed with tissue expander breast reconstruction. Our standard is to only selectively offer tissue expander breast reconstruction to any patient with prior breast radiation due to the high complication rate. However, for patients who have a strong desire to avoid additional scars or more invasive procedures, this study demonstrates that they have an approximately 60 percent chance of success.

Neil A. Fine, M.D.
Northwestern Plastic Surgery Associates
676 North Saint Clair Street, Suite 1525A
Chicago, Ill. 60611
neilfinemd@gmail.com

REFERENCES

1. Kronowitz SJ, Robb GL. Radiation therapy and breast reconstruction: A critical review of the literature. *Plast Reconstr Surg.* 2009;124:395–408.
2. McCarthy CM, Mehrara BJ, Riedel E, et al. Predicting complications following expander/implant breast reconstruction: An outcomes analysis based on preoperative clinical risk. *Plast Reconstr Surg.* 2008;121:1886–1892.
3. Spear SL, Boehmler JH, Bogue DP, et al. Options in reconstructing the irradiated breast. *Plast Reconstr Surg.* 2008;122:379–388.

Copyright © American Society of Plastic Surgeons. Unauthorized reproduction of this article is prohibited.

4. Fine NA, Hirsch EM. Keeping options open for patients with anticipated postmastectomy chest wall irradiation: Immediate tissue expansion followed by reconstruction of choice. *Plast Reconstr Surg.* 2009;123:25–29.
5. Evans GR, Schusterman MA, Kroll SS, et al. Reconstruction and the radiated breast: Is there a role for implants? *Plast Reconstr Surg.* 1995;96:1111–1115; discussion, 1116–1118.
6. Williams JK, Carlson GW, Bostwick J 3rd, et al. The effects of radiation treatment after TRAM flap breast reconstruction. *Plast Reconstr Surg.* 1997;100:1153–1160.
7. Contant CM, van Geel AN, van der Holt B, et al. Morbidity of immediate breast reconstruction (IBR) after mastectomy by a subpectorally placed silicone prosthesis: The adverse effect of radiotherapy. *Eur J Surg Oncol.* 2000;26:344–350.
8. Spear SL, Onyewu C. Staged breast reconstruction with saline-filled implants in the irradiated breast: Recent trends and therapeutic implications. *Plast Reconstr Surg.* 2000;105:930–942.
9. Vandeweyer E, Deraemaecker R. Radiation therapy after immediate breast reconstruction with implants. *Plast Reconstr Surg.* 2000;106:56–58; discussion 59–60.
10. Percec I, Bucky LP. Successful prosthetic breast reconstruction after radiation therapy. *Ann Plast Surg.* 2008;60:527–531.
11. Persichetti P, Cagli B, Simone P, et al. Implant breast reconstruction after salvage mastectomy in previously irradiated patients. *Ann Plast Surg.* 2009;62:350–354.
12. Forman DL, Chiu J, Restifo RJ, et al. Breast reconstruction in previously irradiated patients using tissue expanders and implants: A potentially unfavorable result. *Ann Plast Surg.* 1998;40:360–363; discussion 363–364.
13. Pearl RM, Wisnicki J. Breast reconstruction following lumpectomy and irradiation. *Plast Reconstr Surg.* 1985;76:83–86.

Evidence-Based Medicine: Questions and Answers

Q: I'll do my best to indicate the correct clinical question and Level of Evidence (LOE) on my manuscript. How does the LOE grading process work with *PRS*?

A: The authors' own grading is the first step in the process toward determining the "real" LOE of an article.

Once submitted, manuscripts are peer reviewed as part of the normal review process. *PRS* is training its reviewer panels on how to determine LOE clinical questions and grading. As part of the review process, we will ask our reviewers to indicate their assessment of the LOE for the papers they review. After manuscripts have been reviewed, revised, and accepted for publication, they will be sent to independent evidence-based medicine and LOE experts, who will rate the manuscripts for clinical question and LOE grade. These experts will make the final determination of the LOE of all accepted papers, and their decisions will be reflected in the published LOE of the articles. For those papers that are not gradable, we will leave the LOE grade off of the published abstract.

Copyright © American Society of Plastic Surgeons. Unauthorized reproduction of this article is prohibited.